

See discussions, stats, and author profiles for this publication at: <https://www.researchgate.net/publication/333116305>

# Incidence of Odontocetes with Dorsal Fin Collapse in Maui Nui, Hawaii

Article in *Aquatic Mammals* · May 2019

DOI: 10.1578/AM.45.3.2019.257

CITATIONS

4

READS

629

4 authors:



**Stephanie Stack**  
Griffith University

41 PUBLICATIONS 234 CITATIONS

SEE PROFILE



**Jens Currie**  
Pacific Whale Foundation

42 PUBLICATIONS 306 CITATIONS

SEE PROFILE



**Jessica A. McCordic**  
National Oceanic and Atmospheric Administration

16 PUBLICATIONS 156 CITATIONS

SEE PROFILE



**Grace Olson**  
Pacific Whale Foundation

11 PUBLICATIONS 56 CITATIONS

SEE PROFILE

## **Incidence of Odontocetes with Dorsal Fin Collapse in Maui Nui, Hawaii**

Stephanie H. Stack, Jens J. Currie, Jessica A. McCordic,  
and Grace L. Olson

*Pacific Whale Foundation, 300 Ma'aloa Road, Suite 211, Wailuku, HI 96793, USA*  
*E-mail: research@pacificwhale.org*

### **Abstract**

We examined the incidence of bent or collapsed dorsal fins of eight species of odontocetes observed in the nearshore waters of Maui Nui, Hawaii. Between 1995 and 2017, 1,312 distinctive individual odontocetes were photographically documented. Our photo-identification catalogs include 583 spinner dolphins (*Stenella longirostris longirostris*), 164 bottlenose dolphins (*Tursiops truncatus*), 132 short-finned pilot whales (*Globicephala macrorhynchus*), 253 pantropical spotted dolphins (*Stenella attenuata*), 82 false killer whales (*Pseudorca crassidens*), 70 melon-headed whales (*Peponocephala electra*), 15 pygmy killer whales (*Feresa attenuata*), and 13 rough-toothed dolphins (*Steno bredanensis*). Of these, two false killer whales (2.44% of catalog), two spinner dolphins (0.34% of catalog), and three pantropical spotted dolphins (1.19% of catalog) displayed major dorsal fin disfigurements. Both spinner dolphins and two of the spotted dolphins had multiple resights spanning several years, with one spotted dolphin having a 16-year span between resights. The two false killer whales with bent dorsal fins did not have any resights and were only sighted once throughout the study period. We also present the first progression of dorsal fin collapse after a significant injury to the leading edge of a spinner dolphin. Results from this research expand our knowledge on injuries to marine mammals and the survivorship of wild dolphins with dorsal fin injuries and contribute to the management of odontocetes in Hawaii, where interactions with fishing gear are a significant conservation issue.

**Key Words:** odontocete, disfigurement, dorsal fin, deformity, injury

### **Introduction**

A variety of dorsal fin injuries have been documented in several odontocete species worldwide, but laterally bent or collapsed dorsal fins are a relatively uncommon occurrence (Baird & Gorgone, 2005; Van Waerebeek et al., 2007; Luksenburg, 2014). Dorsal fin collapse is rare in wild populations of odontocetes, with published rates generally less than 1%, if at all present (Baird & Gorgone, 2005). Exceptions to this are well-studied populations of killer whales (*Orcinus orca*) and the main Hawaiian Islands' population of false killer whales (*Pseudorca crassidens*) (Visser, 1998; Alves et al., 2017). A recent publication by Alves et al. (2017) documented 17 species of free-ranging cetaceans with collapsed or bent dorsal fins worldwide. Prior to that publication, bent dorsal fins were under-reported in the literature and only documented anecdotally for wild populations of killer whales (e.g., Visser, 1998; Baird & Stacey, 1989; Matkin et al., 2008), common bottlenose dolphins (*Tursiops truncatus*; Wilson et al., 1997; Baird & Gorgone, 2005), false killer whales (Baird & Gorgone, 2005), white-beaked dolphins (*Lagenorhynchus albirostris*; Higdon & Snow, 2008), and dusky dolphins (*Lagenorhynchus obscurus*; Kugler & Orbach, 2014).

Comparatively, dorsal fin collapse is more commonly found in captive odontocetes such as killer whales (Parsons, 2012). The causes of dorsal fin collapse in captive animals and wild populations are likely different, but both are still not fully understood.

Odontocete dorsal fins are cartilaginous with the thick leading edge providing the most structural support. The collapse of a dorsal fin likely results from breakdown of these supportive cartilaginous fibers. Such breakdown can occur due to acute injury of the leading edge of the dorsal fin or, in cases with no visible injury, breakdown of

fibers due to illness, stress, or age (Visser, 1998; Alves et al., 2017).

Injuries to the dorsal fin in wild populations of odontocetes result from either natural or anthropogenic causes. Natural causes of injury include predation attempts and intraspecific interactions (Visser, 1998). Bent dorsal fins in wild individuals have primarily been attributed to human interactions, either through vessel collisions (Van Waerebeek et al., 2007) or nonlethal entanglement in fishing line (Baird & Gorgone, 2005; Luksenburg, 2014). Fisheries interactions commonly cause injury in odontocetes, particularly via entanglement in fishing line and nets. Such events can be inferred using diagnostic scarring or missing parts of the dorsal fin (e.g., line abrasion scar on false killer whales; Baird & Gorgone, 2005).

The Hawaiian Islands are home to 25 species of cetaceans, including 18 species of odontocetes and seven species of mysticetes (Barlow, 2006). This article reports on instances (or lack thereof) of bent dorsal fins in spinner dolphins (*Stenella longirostris longirostris*), pantropical spotted dolphins (*Stenella attenuata*), bottlenose dolphins, short-finned pilot whales (*Globicephala macrorhynchus*), melon-headed whales (*Peponocephala electra*), pygmy killer whales (*Feresa attenuata*), rough-toothed dolphins (*Steno bredanensis*), and false killer whales using photo-identification collected over a 22-year period. The objectives of this research were to (1) document instances of bent dorsal fins in wild populations of odontocetes in Maui Nui and update the literature with new records, (2) report on the proportion of individuals with bent dorsal fins among species, and (3) present the progression of dorsal fin collapse resulting from an injury.

## Methods

The data for photo-identification were collected from 940 surveys conducted between 1995 and 2017 within the Maui Nui region, consisting of the islands Maui, Molokai, Lanai, and Kahoolawe. The research vessel departed from either Maalaea or Lahaina harbors, Maui, and covered a survey area of 1,145 km<sup>2</sup> (Figure 1). Data were collected during a variety of surveys spanning numerous research studies since 1995, each with a photo-identification aspect. During each survey, up to two observers and the captain scanned the water using a continuous scanning methodology (Mann, 1999) by naked eye, with an additional crew member acting as the data recorder. All surveys were conducted in calm or light wind conditions (less than Beaufort Sea State 4). When

an odontocete was sighted, a focal follow was initiated to identify the species and obtain photographs of the dorsal fins. Each encounter lasted up to an hour or until all individuals within the pod were photographed. Only marked individuals were included in the photo-identification catalog, which consisted of those with distinctive marks on the dorsal fin and identified from good or excellent quality photos (Urian et al., 2015).

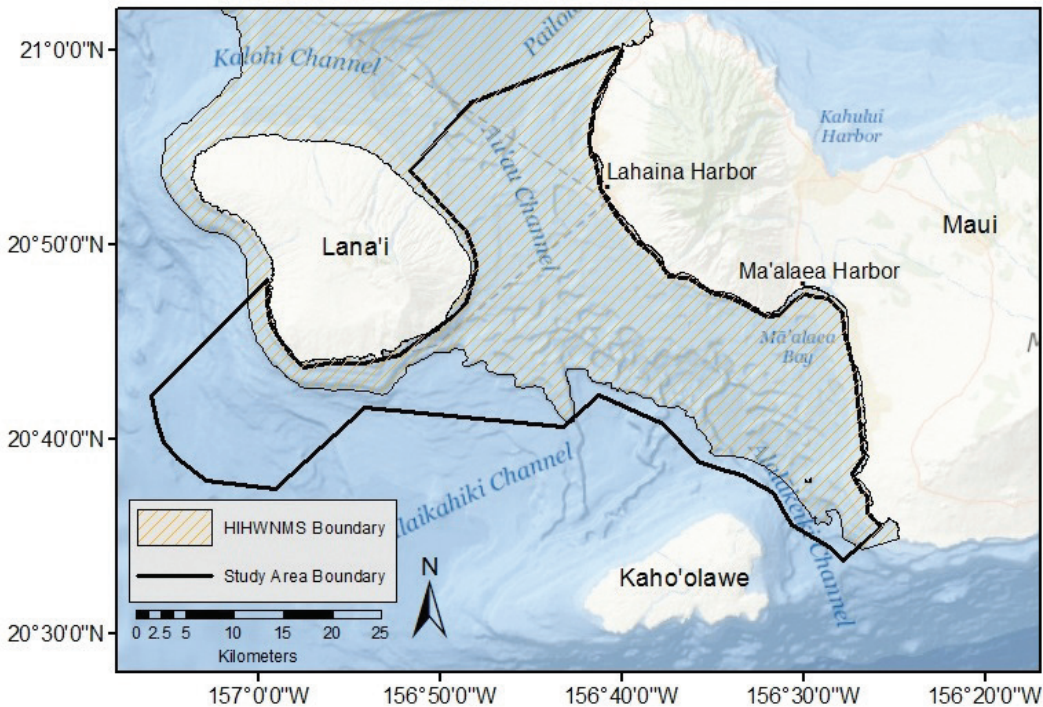
Photographs of marked individuals were visually inspected by two independent researchers and categorized as bent or not bent. Bent dorsal fins were defined as a dorsal fin that is completely or partially bent over laterally (Luksenburg, 2014; Alves et al., 2017). Animals that were known to be neonates or calves were not included due to concerns that the presence of any fetal folds in the dorsal region may affect assessment of bent dorsal fin injuries.

The Fisher's Exact Test was used to determine whether the proportion of animals with bent dorsal fins differs from chance. The overall proportion of animals with bent dorsals was calculated by dividing the number of animals with bent dorsals by the total number of cataloged animals. The 95% confidence intervals (CIs) were calculated using the adjusted Wald method for a binomial estimate of the proportion (Lewis & Sauro, 2006; McCordic et al., 2014). The use of the adjusted Wald method for calculating the CIs of proportions from a small sample allows for the derivation of CIs for a binomial estimate of the proportion rather than presenting just a single point estimate (Agresti & Coull, 1998; Lewis & Sauro, 2006). Although the Exact method of calculating CIs is typically used for very small samples as seen here, it has been found to be over-conservative (Agresti & Coull, 1998). The adjusted Wald method, which provides a more accurate and informative metric, was used.

## Results

A total of 1,312 individuals and eight species were identified (Table 1): false killer whales ( $n = 82$ ), pantropical spotted dolphins ( $n = 253$ ), spinner dolphins ( $n = 583$ ), bottlenose dolphins ( $n = 164$ ), short-finned pilot whales ( $n = 132$ ), melon-headed whales ( $n = 70$ ), pygmy killer whales ( $n = 15$ ), and rough-toothed dolphins ( $n = 13$ ). Of the cataloged individuals, bent dorsal fins were only observed in seven individuals distributed among three species: two false killer whales, two spinner dolphins, and three spotted dolphins (Figure 2; Table 1).

None of the bottlenose dolphins, short-finned pilot whales, melon-headed whales, pygmy killer whales, or rough-toothed dolphins identified during the study period were observed with bent



**Figure 1.** Map depicting the survey area boundary used to study odontocetes from 1995 to 2017 as well as the extent of the Hawaiian Islands Humpback Whale National Marine Sanctuary (HIHWNMS) in Maui Nui, Hawaii. Map created using *ArcGIS Desktop*, Version 10.5.1 ([www.esri.com](http://www.esri.com)).

dorsal fins. Of the three spotted dolphins with bent fins (#014, #021, and #197), two were seen in multiple years: spotted dolphin #014 was sighted in two consecutive years, and spotted dolphin #021 was sighted eight separate times between 1998 and 2017. The third spotted dolphin (#197) was only sighted once. Both spinner dolphins with this condition (#079 and #295) were seen over multiple years: spinner dolphin #295 was sighted in three consecutive years, and spinner dolphin #079 was seen over a span of 15 years. Both false killer whales (#025 and #028) with bent dorsal fins were only encountered once (Table 2).

The proportion of individuals with bent dorsal fins did not significantly differ across all of these species (Fisher's Exact Test,  $p = 0.055$ ), and pairwise comparisons were nonsignificant for all the tests (Fisher's Exact Test, false killer whales–spotted dolphins:  $p = 0.599$ ; false killer whales–spinner dolphins:  $p = 0.076$ ; spotted dolphins–spinner dolphins:  $p = 0.166$ ).

The majority of the individuals that displayed this condition were either adult or unknown age-class (but not calves) and of unknown sex; however, false killer whale #025 was known to be an

adult female. No other obvious external physical injury or deformity (e.g., emaciation, entanglement, or boat propeller scars) was noted for any of the individuals with bent dorsal fins.


Spinner dolphin #079 has a 15-year resight history, which allowed us to observe the progression of dorsal fin collapse after a significant injury to the leading edge (Figure 3). When initially observed with a large notch missing from the leading edge of the upright dorsal fin on 17 July 1996, the dolphin appeared to be in good health with no obvious signs of emaciation. Despite the damage to the leading edge, the dorsal fin remained upright from 27 July 1996 to 15 July 1999. The next sighting of the individual was on 18 February 2010, at which point the upper portion of the dorsal fin had collapsed. However, the lack of resights before the injury and from 1999 to 2010 suggests the process may take even longer.

**Table 1.** Proportion of bent dorsal fins for individuals cataloged in Maui Nui between 1995 and 2017 (this study) and population estimates from published literature

Species	No. of marked individuals (No. with bent dorsal fins)	% of cataloged with bent dorsal fin (Adj. Wald 95% CI)	Estimated population size
<i>Pseudorca crassidens</i>	82 (2)	2.44 (0.15-8.98)	151 <sup>1</sup> (MHI)
<i>Stenella attenuata</i>	253 (3)	1.19 (0.24-3.59)	4,283 <sup>2</sup> (MHI)
<i>Stenella longirostris</i>	583 (2)	0.36 (0.01-1.33)	1,713 <sup>2</sup> (MHI)
<i>Tursiops truncatus</i>	164 (0)	0	191 <sup>3</sup> (MN)
<i>Globicephala macrorhynchus</i>	132 (0)	0	19,503 <sup>4</sup> (HEEZ)
<i>Peponocephala electra</i>	70 (0)	0	8,666 <sup>4</sup> (HEEZ)
<i>Feresa attenuata</i>	15 (0)	0	10,640 <sup>4</sup> (HEEZ)
<i>Steno bredanensis</i>	13 (0)	0	72,528 <sup>4</sup> (HEEZ)

<sup>1</sup>Oleson et al., 2010; <sup>2</sup>Barlow, 2006; <sup>3</sup>Baird et al., 2009; <sup>4</sup>Bradford et al., 2017

**Note:** The number of marked individuals includes only distinctive adults or subadults based on marks on the dorsal fin and with good or excellent quality photos. Proportions presented with 95% CIs were calculated using adjusted Wald method as in McCordic et al. (2014). MN = Maui Nui, MHI = Main Hawaiian Islands, and HEEZ = Hawaii Islands Economic Exclusive Zone.



**Figure 2.** Identification photographs of individuals exhibiting bent dorsal fins: (A) false killer whales, (B) spotted dolphins, and (C) spinner dolphins. Note that each photograph represents a different individual. All photographs were taken by a researcher under NMFS research permit.

**Table 2.** Summary of information available for seven individual odontocetes with bent dorsal fins

Species	Catalog ID	Max. years between sightings	Age-class	Location of dorsal fin injuries
<i>Pseudorca crassidens</i>	#025	NA	Unknown	Base; leading edge
	#028	NA	Unknown	Base
<i>Stenella attenuata</i>	#014	1	Adult	Trailing edge
	#021	16	Adult	Leading edge
	#197	< 1	Adult	Leading edge
<i>Stenella longirostris</i>	#079	15	Unknown	Leading edge
	#295	2	Unknown	Leading edge

**Figure 3.** Progression of dorsal fin bending arising from an injury to the leading edge of spinner dolphin #079 in Maui Nui, Hawaii. All photographs were taken by a researcher under NMFS research permit.

## Discussion

This is the first published instance of a bent dorsal fin in either a pantropical spotted dolphin or a spinner dolphin. Neither of the previous studies addressing bent dorsal fins in odontocetes of the Hawaiian Islands (Baird & Gorgone, 2005; Alves et al., 2017) have included pantropical spotted dolphins in their analyses. Baird & Gorgone (2005) report no bent dorsal fins in spinner dolphins; however, it is possible that they assessed a different island-associated group (e.g., Andrews et al., 2010). Further, spinner dolphin #079 represents the first documentation of dorsal fin collapse progression for any odontocete species. The dorsal fin collapse in this scenario likely arose from the physical trauma to the leading edge of the dorsal fin and resulting gradual breakdown of cartilage over several years (Alves et al., 2017).

Instances of bent dorsal fins were not observed to be significantly more prevalent in any of the three species of odontocetes with individuals displaying the condition. This is likely the result of the overall low rate of occurrence across the three species studied here as well as in other odontocete species (Alves et al., 2017). Although our results do not show significant differences in the proportion of affected individuals among species, we observed a similar pattern as registered in the literature (Baird & Gorgone, 2005), with false killer whales having the highest prevalence of individuals with bent dorsal fins. In Maui Nui, false killer whales have twice the proportion of individuals with bent dorsal fins when compared to pantropical spotted dolphins and seven times the proportion of individuals when compared to spinner dolphins. This relatively high proportion of bent dorsal fins in false killer whales has been noted in previous research (Baird & Gorgone, 2005; Alves et al., 2017) and constitutes a significant conservation issue for the species due to the relationship between dorsal fin injuries and fisheries interactions.

It is important to note that the power to detect differences when dealing with small proportions is difficult (Ellis, 2010) and should be considered when interpreting these results. Most wild populations of odontocetes do not seem to include individuals with bent dorsal fins. Only three of the eight odontocete species examined in this study had individuals with this condition. Although Alves et al. (2017) reported a single bottlenose dolphin with a bent dorsal fin in Hawaii, that individual, HITt302, was part of a social cluster associated with the island of Hawaii and would not likely have been seen in our study area (Baird et al., 2009). Baird & Gorgone (2005) reported bent dorsal fins in two of the 16 odontocete

species they assessed in Hawaii. Odontocetes with bent dorsal fins are very conspicuous in the field, so it is unlikely that (1) if sighted, individuals with bent dorsal fins would not have been photographed and (2) resightings of those individuals would be missed during cataloging. As such, bent dorsal fins in free-ranging cetaceans are not as prevalent as in captive cetaceans (Parsons, 2012) but appear to occur in certain species more than others.

Five out of the seven individuals with bent dorsal fins did not have a long sighting history. This may result from low resighting rates and not necessarily be due to the collapsed dorsal fin. Both of the false killer whales (#025 and #028) and a single spotted dolphin (#197) were only seen during a single year, and it is worth noting that these two species have the lowest resighting rate of our cataloged species, with an average of 1.7 (SD = 1.6) and 1.65 (SD = 1.1) resights per individual, respectively. The false killer whale #025, photographed on 29 March 1999, is also known as HIPc186 by the Cascadia Research Collective. This individual was reported to have a bent dorsal fin when it was tagged in December 2009 (Baird & Gorgone, 2005; Baird et al., 2011), demonstrating a survivorship of approximately 10 years. The long duration between sightings of individuals from all three species with bent dorsal fins suggests that odontocetes can survive this injury, but the observed incidence of this condition represents the minimum number of cases as there could be others that were fatal and therefore not reported.

The long-term effects of this condition are unknown and will likely vary depending on the species and causation; however, it is possible that having a bent dorsal fin could cause serious problems for affected individuals. The dorsal fin is thought to aid in stability while swimming and functions optimally when upright (Fish, 1998; Kastelein et al., 2016), so these odontocetes may suffer from a reduced capacity to forage or evade predators. Vascular arrangement within the dorsal fin has also been suggested to be important for thermoregulation, allowing cetaceans to bypass countercurrent heat exchange systems and dissipate excess body heat (Kastelein et al., 1997; Meagher et al., 2002). Indeed, the highest heat flux occurs at the distal tip of the dorsal fin (Meagher et al., 2002), and severe injuries to the dorsal fin that reduce or alter blood flow to the tip of the fin may reduce the ability of those individuals to regulate their internal body temperature (Kastelein et al., 2016).

Physical injuries from boat strikes, entanglement, and fisheries interactions may cause bending

of the dorsal fin, but the individuals presented herein did not have any other obvious physical injury or deformities in areas other than the dorsal fin. All animals recorded with a bent dorsal fin did exhibit physical injuries on the dorsal fin or at the base of the dorsal fin, but this finding is not surprising as we only examined individuals considered “marked” for photographic identification, and “clean” dorsal fins were excluded from the analysis. Of note is that 71.42% of these animals had injuries on the leading edge of the dorsal fin that were in the same location as the fin bending (Figure 2). The exact cause of the injury is unknown, but previous literature has defined fisheries interaction scars as single linear injuries often at the leading edge or base of the dorsal fin and parallel to the body axis (Baird & Gorgone, 2005; Kiszka et al., 2008; Baird et al., 2015). Further, Baird (2016) noted fisheries interactions for both pantropical spotted dolphins and false killer whales.

In our study, the linear nature of the injury and long striation down the dorsal fin in each of these animals suggests the cause is likely a fisheries interaction. Although our small sample size and limited photographic evidence preclude inferences of causation, bycatch is a known threat to the Main Hawaiian Islands’ distinct population segment of false killer whales, with most reported interactions occurring with the long-line tuna fishery (Baird et al., 2015). Bycatch and other fisheries interactions have also been noted in other Hawaiian odontocete species, including spotted dolphins, spinner dolphins, bottlenose dolphins, and rough-toothed dolphins (Nitta & Henderson, 1993; Luksenburg, 2014). Exposure to stress and/or illness have also been theorized as potential causes for this condition in other species (e.g., Bigg, 1982; Berghan & Visser, 2000; Baird & Gorgone, 2005; Higdon & Snow, 2008; Kastelein et al., 2016). A reduction in nutrient intake and/or blubber thickness could also influence dorsal fin bending and collapse as an emaciated body condition can lead to looser skin tensions around the base of the dorsal fin (e.g., Kastelein et al., 1997; Berghan & Visser, 2000; Baird & Gorgone, 2005; Higdon & Snow, 2008; Kastelein et al., 2016).

Bent dorsal fins should be used in assessing the health of a population because, even at low rates, this condition could impact populations such as the endangered false killer whales, of which there are an estimated 150 to 200 in the Main Hawaiian Islands (Bradford et al., 2018), or spinner dolphins, which are facing increasing pressures from high levels of human activity (Tyne et al., 2018). Our observations of an individual surviving 16 years with a bent dorsal fin

suggest these disfigurements are not necessarily fatal but could affect an animal’s ability to swim, forage, and reproduce (Rommel et al., 1993; Baird & Gorgone, 2005), even when individuals can survive the initial injury. Alves et al. (2017) noted that “it would be valuable for researchers to document and share information on individuals with bent dorsal fins or other striking physical abnormalities in general” (p. 6) and that further studies would help determine survivorship. The results reported herein contribute valuable data on an under-reported metric in the literature that has important conservation implications. This condition should be explored with greater reporting and long-term monitoring as increased documentation will be important in determining the causes and incidence of dorsal fin collapse in wild cetacean populations.

### Notes

SHS conceived the study. All authors contributed to writing the main text, and JAM and JJC prepared the figures and tables. The authors declare that no conflict of interest exists.

### Acknowledgments

We thank the members and supporters of Pacific Whale Foundation for providing the funding for this study. We also thank the anonymous reviewers who reviewed this manuscript and provided constructive feedback which greatly improved the final product.

### Literature Cited

- Agresti, A., & Coull, B. A. (1998). Approximate is better than “exact” for interval estimation of binomial proportions. *The American Statistician*, 52(2), 119-126. <https://doi.org/10.1080/00031305.1998.10480550>
- Alves, F., Towers, J. R., Baird, R. W., Bearzi, G., Bonizzoni, S., Ferreira, R., . . . Dinis, A. (2017). The incidence of bent dorsal fins in free-ranging cetaceans. *Journal of Anatomy*, 232(2), 263-269. <https://doi.org/10.1111/joa.12729>
- Andrews, K. R., Karczmarski, L., Au, W. W. L., Rickards, S. H., Vanderslip, C. A., Bowen, B. W., . . . Toonen, R. J. (2010). Rolling stones and stable homes: Social structure, habitat diversity and population genetics of the Hawaiian spinner dolphin (*Stenella longirostris*). *Molecular Ecology*, 19(4), 732-748. <https://doi.org/10.1111/j.1365-294X.2010.04521.x>
- Baird, R. W. (2016). *The lives of Hawaii’s dolphins and whales: Natural history and conservation*. Honolulu: University of Hawaii Press. 352 pp.
- Baird, R. W., & Gorgone, A. M. (2005). False killer whale dorsal fin disfigurements as a possible indicator of long-line fishery interactions in Hawaiian waters.



- Pacific Science*, 59(4), 593-601. <https://doi.org/10.1353/psc.2005.0042>
- Baird, R. W., & Stacey, P. J. (1989). Observations on the reactions of sea lions, *Zalophus californianus* and *Eumetopias jubatus*, to killer whales, *Orcinus orca*; evidence of "prey" having a "search image" for predators. *Canadian Field-Naturalist*, 103, 426-428.
- Baird, R. W., Schorr, G. S., Webster, D. L., McSweeney, D. J., Hanson, M. B., & Andrews, R. D. (2011). *Movements and spatial use of false killer whales in Hawaii: Satellite tagging studies in 2009* (DTIC Document No. AB133F09SE4132). Olympia, WA: Cascadia Research Collective. <https://doi.org/10.21236/ADA539300>
- Baird, R. W., Gorgone, A. M., McSweeney, D. J., Ligon, A. D., Deakos, M. H., Webster, D. L., . . . Mahaffy, S. D. (2009). Population structure of island-associated dolphins: Evidence from photo-identification of common bottlenose dolphins (*Tursiops truncatus*) in the main Hawaiian Islands. *Marine Mammal Science*, 25(2), 251-274. <https://doi.org/10.1111/j.1748-7692.2008.00257.x>
- Baird, R. W., Mahaffy, S. D., Gorgone, A. M., Cullins, T., McSweeney, D. J., Oleson, E. M., . . . Webster, D. L. (2015). False killer whales and fisheries interactions in Hawaiian waters: Evidence for sex bias and variation among populations and social groups. *Marine Mammal Science*, 31(2), 579-590. <https://doi.org/10.1111/mms.12177>
- Barlow, J. (2006). Cetacean abundance in Hawaiian waters estimated from a summer/fall survey in 2002. *Marine Mammal Science*, 22(2), 446-464. <https://doi.org/10.1111/j.1748-7692.2006.00032.x>
- Berghan, J., & Visser, I. N. (2000). Vertebral column malformations in New Zealand delphinids: With a review of cases worldwide. *Aquatic Mammals*, 26(1), 17-25.
- Bigg, M. A. (1982). An assessment of killer whale (*Orcinus orca*) stocks off Vancouver Island, British Columbia. *International Whaling Commission Report of the Commission*, 32, 655-666.
- Bradford, A. L., Forney, K. A., Oleson, J. E. M., & Barlow, J. (2017). Abundance estimates of cetaceans from a line-transect survey within the U.S. Hawaiian Islands Exclusive Economic Zone. *Fishery Bulletin*, 115(2), 129-142. <https://doi.org/10.7755/FB.115.2.1>
- Bradford, A. L., Baird, R. W., Mahaffy, S. D., Gorgone, A. M., McSweeney, D. J., Cullins, T., . . . Zerbini, A. Z. (2018). Abundance estimates for management of endangered false killer whales in the main Hawaiian Islands. *Endangered Species Research*, 36, 297-313.
- Ellis, P. D. (2010). *The essential guide to effect sizes: Statistical power, meta-analysis, and the interpretation of research results*. Cambridge, UK: Cambridge University Press. 193 pp. <https://doi.org/10.1017/CBO9780511761676>
- Fish, F. E. (1998). Comparative kinematics and hydrodynamics of odontocete cetaceans: Morphological and ecological correlates with swimming performance. *Journal of Experimental Biology*, 201, 2867-2877.
- Higdon, J. W., & Snow, D. (2008). First record of a collapsed dorsal fin in a white-beaked dolphin, *Lagenorhynchus albirostris*, with a gunshot wound as a possible cause. *Canadian Field-Naturalist*, 122(3), 262-264. <https://doi.org/10.22621/cfn.v122i3.609>
- Kastelein, R. A., Triesscheijn, R. J. V., & Jennings, N. (2016). Reversible bending of the dorsal fins of harbor porpoises (*Phocoena phocoena*) and a striped dolphin (*Stenella coeruleoalba*) in captivity. *Aquatic Mammals*, 42(2), 218-226. <https://doi.org/10.1578/AM.42.2.2016.218>
- Kastelein, R. A., Dubbeldam, J. L., Luksenburg, J., Staal, C., & van Immerseel, A. A. H. (1997). An anatomical atlas of an adult female harbour porpoise (*Phocoena phocoena*). In A. J. Read, P. R. Wiepkema, & P. E. Nachtigall (Eds.), *The biology of the harbour porpoise* (pp. 87-178). Woerden, The Netherlands: De Spil Publishers.
- Kiszka, J., Pelourdeau, D., & Ridoux, V. (2008). Body scars and dorsal fin disfigurements as indicators of interaction between small cetaceans and fisheries around the Mozambique Channel Island of Mayotte. *Western Indian Journal of Marine Science*, 7(2), 185-193.
- Kugler, A., & Orbach, D. N. (2014). Sources of notch and scar patterns on the dorsal fins of dusky dolphins (*Lagenorhynchus obscurus*). *Aquatic Mammals*, 40(3), 260-273. <https://doi.org/10.1578/AM.40.3.2014.260>
- Lewis, J. R., & Sauro, J. (2006). When 100% really isn't 100%: Improving the accuracy of small-sample estimates of completion rates. *Journal of Usability Studies*, 3(1), 136-150.
- Luksenburg, J. A. (2014). Prevalence of external injuries in small cetaceans in Aruban waters, southern Caribbean. *PLOS ONE*, 9(2), e88988. <https://doi.org/10.1371/journal.pone.0088988>
- Mann, J. (1999). Behavioral sampling methods for cetaceans: A review and critique. *Marine Mammal Science*, 15(1), 102-122. <https://doi.org/10.1111/j.1748-7692.1999.tb00784.x>
- Matkin, C. O., Saulitis, E. L., Ellis, G. M., Olesiuk, P., & Rice, S. D. (2008). Ongoing population-level impacts on killer whales *Orcinus orca* following the "Exxon Valdez" oil spill in Prince William Sound, Alaska. *Marine Ecology Progress Series*, 356, 269-281. <https://doi.org/10.3354/meps07273>
- McCordic, J. A., Todd, S. K., & Stevick, P. T. (2014). Differential rates of killer whale attacks on humpback whales in the North Atlantic as determined by scarification. *Journal of the Marine Biological Association of the United Kingdom*, 94(6), 1311-1315. <https://doi.org/10.1017/S0025315413001008>
- Meagher, E. M., McLellan, W. A., Westgate, A. J., Wells, R. S., Frierson, D., Jr., & Pabst, D. A. (2002). The relationship between heat flow and vasculature in the dorsal fin of wild bottlenose dolphins *Tursiops truncatus*. *Journal of Experimental Biology*, 205, 3475-3486.
- Nitta, E. T., & Henderson, J. R. (1993). A review of interactions between Hawaii's fisheries and protected species. *Marine Fisheries Review*, 55(2), 83-92.

- Oleson, E. M., Boggs, C. H., Forney, M. B., Forney, K. A., Hanson, M. B., Kobayashi, D. R., . . . Ylitalo, G. M. (2010). *Status review of Hawaiian insular false killer whales (Pseudorca crassidens) under the Endangered Species Act* (NOAA Technical Memo NOAA-TM-NMFS-PIFSC-22). Washington, DC: National Oceanic and Atmospheric Administration.
- Parsons, E. C. M. (2012). *An introduction to marine mammal biology and conservation*. Sudbury, MA: Jones & Bartlett Publishing.
- Rommel, S. A., Pabst, D. A., & McLellan, W. A. (1993). Functional morphology of the vascular plexuses associated with the cetacean uterus. *The Anatomical Record*, 237(4), 538-546. <https://doi.org/10.1002/ar.1092370414>
- Tyne, J. A., Christiansen, F., Heenehan, H. L., Johnston, D. W., & Bejder, L. (2018). Chronic exposure of Hawaii Island spinner dolphins (*Stenella longirostris*) to human activities. *Open Science*, 5(10), 171506. <https://doi.org/10.1098/rsos.171506>
- Urian, K., Gorgone, A., Read, A., Balmer, B., Wells, R. S., Berggren, P., . . . Hammond, P. S. (2015). Recommendations for photo-identification methods used in capture-recapture models with cetaceans. *Marine Mammal Science*, 31(1), 298-321. <https://doi.org/10.1111/mms.12141>
- Van Waerebeek, K., Baker, A. N., Félix, F., Gedamke, J., Iñiguez, M., Sanino, G. P., . . . Wang, Y. (2007). Vessel collisions with small cetaceans worldwide and with large whales in the Southern Hemisphere, and initial assessment. *Latin American Journal of Aquatic Mammals*, 6(1), 43-69. <https://doi.org/10.5597/lajam00109>
- Visser, I. N. (1998). Prolific body scars and collapsing dorsal fins on killer whales (*Orcinus orca*) in New Zealand waters. *Aquatic Mammals*, 24(2), 71-81.
- Wilson, B., Thompson, P. M., & Hammond, P. S. (1997). Skin lesions and physical deformities in bottlenose dolphins in the Moray Firth: Population prevalence and age-sex differences. *Ambio*, 26, 243-247.